



Characteristics, surgical outcomes, and influential factors in

Zhou,

1

Changqing Liu,¹ Yongxing Sun,⁵ Mingwang Zhu,⁶ Xueling Qi,⁷ Guoming Luan^{1,3,4} and Yuguang Guan^{1,3,4}

Few studies have reported the clinical presentation, surgical treatment, outcomes and influential factors for patients with epilepsy and Sturge-Weber syndrome.

This large-scale retrospective study continuously enrolled 132 patients with Sturge-Weber syndrome and epilepsy from January 2008 to December 2018 at our hospital to analyse their characteristics. Among these patients, 90 underwent epilepsy surgery, and their postoperative 2-year follow-up seizure, cognitive and motor functional outcomes were assessed and analysed. Univariable and multivariable logistic analyses were conducted to explore the influential factors.

Among the patients with Sturge-Weber syndrome for whom characteristics were analysed ($n = 132$), 76.52% of patients had their first epileptic seizures within their first year of life. The risk factors for cognitive decline were seizure history ≥ 2 years [adjusted odds ratio (aOR) = 3.829, 95% confidence interval (CI): 1.810–9.021, $P = 0.008$], bilateral leptomeningeal angiomias (aOR = 3.173, 95% CI: 1.970–48.194, $P = 0.013$), age at onset < 1 year (aOR = 2.903, 95% CI: 1.230–6.514, $P = 0.013$), brain calcification (aOR = 2.375, 95% CI: 1.396–5.201, $P = 0.021$) and left leptomeningeal angiomias (aOR = 2.228, 95% CI: 1.351–32.571, $P = 0.030$). Of the patients who underwent epilepsy surgery ($n = 90$), 44 were subject to focal resection, and 46 underwent hemisphere surgery (19 anatomical hemispherectomies and 27 modified hemispherotomies). A postoperative seizure-free status, favourable cognitive outcomes, and favourable motor outcomes were achieved in 83.33%, 44.44% and 43.33% of surgical patients, respectively. The modified hemispherotomy group had similar surgical outcomes, less intraoperative blood loss and shorter postoperative hospital stays than the anatomical hemispherectomy group. Regarding seizure outcomes, full resection (aOR = 11.115, 95% CI: 1.260–98.067, $P = 0.020$) and age at surgery < 2 years (aOR = 6.040, 95% CI: 1.444–73.367, $P = 0.031$) were positive influential factors for focal resection. Age at surgery < 2 years (aOR = 15.053, 95% CI: 1.050–215.899, $P = 0.036$) and infrequent seizures (aOR = 8.426, 95% CI: 1.086–87.442, $P = 0.042$; monthly versus weekly) were positive influential factors for hemisphere surgery.

In conclusion, epilepsy surgery resulted in a good postoperative seizure-free rate and favourable cognitive and motor functional outcomes and showed acceptable safety for patients with epilepsy and Sturge-Weber syndrome. Modified hemispherotomy is a less invasive and safer type of hemisphere surgery than traditional anatomic hemispherectomy with similar surgical outcomes. Early surgery may be helpful to achieve better seizure outcomes and cognitive protection, while the risk of surgery for young children should also be considered.

1 Department of Neurosurgery, SanBo Brain Hospital, Capital Medical University, Beijing 100093, China

2 Department of Neurology, SanBo Brain Hospital, Capital Medical University, Beijing 100093, China

3 Beijing Key Laboratory of Epilepsy, Beijing 100093, China

4 Center of Epilepsy, Beijing Institute of Brain Disorders, Collaborative Innovation Center for Brain Disorders, Capital Medical University, Beijing 100093, China

- 5 Department of Anesthesiology, SanBo Brain Hospital, Capital Medical University, Beijing 100093, China
 6 Department of Radiology, SanBo Brain Hospital, Capital Medical University, Beijing 100093, China
 7 Department of Pathology, SanBo Brain Hospital, Capital Medical University, Beijing 100093, China

Correspondence to: Yuguang Guan
 Department of Neurosurgery, SanBo Brain Hospital
 Capital Medical University
 Beijing 100093, China
 E-mail: guanyg2020@ccmu.edu.cn

Correspondence may also be addressed to: Guoming Luan
 Department of Neurosurgery, SanBo Brain Hospital
 Capital Medical University
 Beijing 100093, China
 E-mail: luangm@ccmu.edu.cn

Keywords: Sturge-Weber syndrome; epilepsy; seizure; surgery; outcome

Abbreviations: AH = anatomical hemispherectomy; AED = anti-epileptic drug; FCD = focal cortical dysplasia; FR = focal resection; HS = hemisphere surgery; MH = modified hemispherotomy; SWS = Sturge-Weber syndrome

Introduction

Sturge-Weber syndrome (SWS) is a rare congenital neurocutaneous disorder affecting approximately 0.19 in 100 000 people per year.¹ Somatic mutations during foetal development may contribute to the etiopathogenesis of SWS.^{2–4} Typical clinical presentations of SWS are port-wine stains and other microvascular malformations affecting the skin (mainly characterized by facial angiomas) and CNS (mainly characterized by leptomeningeal angiomas).^{5,6} Patients with SWS may also have complications such as glaucoma, epilepsy, motor defects, cognitive decline and other neurological defects.^{4,6,7}

Previous studies have revealed that 75–100% of children with SWS have epilepsy.^{6,8} Notably, 30–52% of patients with SWS develop refractory epilepsy, which cannot be resolved by anti-epileptic drugs (AEDs).^{6,9,10} For SWS patients with refractory epilepsy, epilepsy surgery is a widely accepted treatment strategy.^{5,11–15} However, given its low incidence, most of these studies included only a small number of patients with SWS, and these data do not provide a complete understanding of the indications, types, outcomes and influential factors associated with the surgery.^{5,9}

For this study, we enrolled 132 patients with SWS and epilepsy to analyse the clinical presentation of this condition and factors that influence it. These findings may provide a better understanding of this rare disorder. Additionally, this study included 90 surgical patients to further explore available surgical treatments, patient outcomes and influential factors.

Materials and methods

Patient population and inclusion criteria

This retrospective study continuously enrolled patients diagnosed with SWS and epilepsy between January 2008 and December 2018 at Sanbo Brain Hospital, Capital Medical University, Beijing, China. The institutional ethics committee approved the study. All patients included in the study, or their guardians, were informed previously, agreed to participate and provided written informed consent for surgery and the collection

of anonymized data for scientific purposes. This study was conducted following the tenets outlined in the 1964 Declaration of Helsinki and its later amendments.

All patients diagnosed with SWS and epilepsy were included to analyse the clinical characteristics of the disease. The inclusion criteria were patients diagnosed with SWS by at least two qualified senior neurology and neurosurgery specialists according to clinical presentation and neuroimaging [i.e. patients with the presence of facial angiomas (also called port-wine stains) and leptomeningeal angioma (usually accompanied by brain calcifications and cortical atrophy based on neuroimaging findings) with or without glaucoma; and patients with only isolated intracranial or facial involvement].^{5,16–20} Patients who did not provide written informed consent were excluded from this study.

Among these patients, those who underwent epilepsy surgery [i.e. focal resection (FR) or hemisphere surgery (HS)] were then entered into surgical treatment analyses. The inclusion criteria required these surgical patients to meet the following surgical indications. (i) Patients who had motor defects or cognitive decline were required to have refractory epilepsy, which was defined as the failure of adequate trials of at least two tolerated, appropriately chosen and used AED schedules for at least 6 months^{5,13,21}; however, early refractory status epilepticus, which was defined as the continuation of status epilepticus (abnormally continuous disabling seizures after 30 min, International League Against Epilepsy definition 2015²²) after receiving adequate doses of initial benzodiazepines followed by a second acceptable AED,^{22–24} was also considered an indication for epilepsy surgery even before the 6-month AED trial period due to the risk of catastrophic epilepsy and associated neurocognitive decline.^{5,13} For patients who showed no motor defects or cognitive decline, a prolonged 24-month period of the AED trial was taken to ensure drug resistance.²¹ After that, surgical treatment was considered. (ii) The surgical area could be determined by detailed presurgical assessments. (iii) After evaluating the risks of surgery and anaesthesia, the neurosurgeons and anaesthesiologists recommended surgical treatment. (iv) The patient or his/her guardians agreed to surgery and provided informed consent. Patients with bilateral involvement (i.e. bilateral lesions, which were suggested by CT or MRI, or highly suspicious bilateral

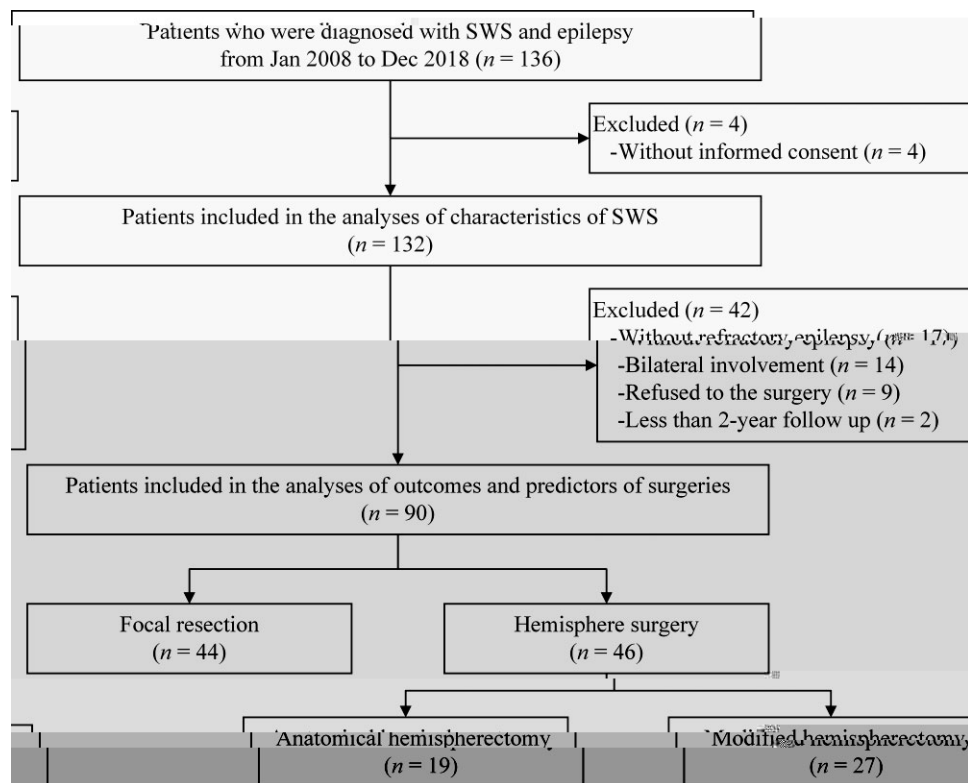


Figure 1 Flow diagram of the enrollment procedure of patients with SWS.

epileptic involvement, which was suggested as semiology opposing focal or unilateral MRI or CT lesions) were not considered for epilepsy surgery. After the surgery, patients who completed less than 2 years of follow-up or who did not complete the assessments were excluded. Figure 1 shows the enrollment flow chart.

Presurgical assessments

Experienced neurologists and neurosurgeons performed routine assessments after the patients were admitted to the hospital. The baseline characteristics and information on clinical presentation (including the clinical history, seizures, angiomas, glaucoma and other symptoms) were collected. The Roach Scale was used for SWS classification. Type I patients have both facial and leptomeningeal angiomas. Type II patients have isolated facial angioma (no CNS involvement). Type III patients have isolated leptomeningeal angioma.⁵ The seizure types were classified based on the International League Against Epilepsy seizure classification 2017.²⁵ Seizure clustering was defined according to the study by Kossoff *et al.*²⁶ as 'multiple seizures recurring over a 24-h period or a prolonged seizure ≥ 30 min at least once in their lifetime'.

The presurgical neuroimaging modalities utilized included CT scans (2-mm, axial, Philips) and MR images (1.5-T, Siemens or 3.0-T, GE). All the patient MRI sequences were T₁-weighted images (5-mm, sagittal and axial) and enhanced images (gadolinium-DTPA; 5-mm, sagittal, axial and coronal), T₂-weighted images (5-mm, axial; 3-mm, coronal), fluid-attenuated inversion recovery (FLAIR; 5-mm, sagittal and axial; 3-mm, coronal) and diffusion-weighted images/apparent diffusion coefficient (5-mm, axial). These sequences were also applied as postoperative assessments. All patients had undergone 16–72 h of 64-channel concurrent video and EEG (video-EEG). The patients' motor function was assessed based on neurological

examination to determine whether gross motor functioning and dexterity were age-appropriate. Additionally, all the patients were required to undergo cognitive function assessment. The Denver Developmental Screening Test-II is a screening assessment of cognitive function for children aged <6 years comprising four domains. Patients with cognitive decline are defined as 'Abnormal: falling behind in peer groups in any domain' or 'Doubtful: there are suspected abnormalities in some domains'. Patients who achieved 'Normal: none of the above' on the Denver Developmental Screening Test-II were considered to have normal cognitive function, whereas the other patients were considered to show cognitive decline.²⁷ For patients ≥ 6 years, the Wechsler Children Intelligence Scale-IV (for patients aged <16 years) or the Wechsler Adult Intelligence Scale-IV (for patients aged ≥ 16 years) were used to assess the intelligence quotient (IQ).^{28,29} All the scales were Chinese versions and were revised for local populations.³⁰ The suitable classification standards of normal or declined cognitive function were determined by consensus after review by neuropsychology specialists with reference to Chinese norms.³¹ Additionally, all the patients were evaluated using a neurologic score described by Kelley *et al.*¹⁷ at baseline, which involved three domains: seizure (possible score of 0–4), cognition (possible score of 0–5) and hemiparesis (possible score of 0–4). A higher score indicates more severe clinical symptoms in this domain.

Surgical strategy

The surgical plan, type and resection area were determined together with a multidisciplinary team comprising neurosurgeons, neurologists, radiologists, electrophysiologists and psychologists. The main principle of epilepsy surgery is the attempt to remove epileptogenic lesions (i.e. vascular malformations and adjacent calcified parenchyma on presurgical CT or MRI and intraoperative

findings, combined with the consideration of semiology and video-EEG).

Two types of epilepsy surgery were performed under general anaesthesia, FR and HS; the type of surgery performed was determined by the resection area. For resection areas involving only focal areas or several brain lobes, FR was performed following a standard procedure of lobe resection, such as temporal lobectomy, occipital lobectomy and their combination. For patients with unilateral hemisphere involvement, two types of HS were considered: anatomical hemispherectomy (AH) and modified hemispherotomy (MH). Patients who underwent AH had the whole affected hemisphere removed following a standard surgical procedure. The patient was placed in a lateral position, and a craniotomy was performed with a bone flap in the frontotemporal parieto-occipital region. The bone flap was less than 1.5 cm from the midline and was flush with the temporal base. First, all M2–M3 branches of the middle cerebral artery were cut, the bottom of the forehead was lifted and the distal end of the ipsilateral anterior cerebral artery A2 branch was cut off. Second, after entering the lateral ventricle temporal horn from the inferior insula sulcus, the branch of the posterior cerebral artery was removed according to the hippocampus outer edge. Third, the connection between the ipsilateral hemisphere and thalamus was disconnected using the peri-insular technique, and all of the veins of the frontal, temporal, parietal and occipital hemispheres were excised. Fourth, the cerebral hemispheres were removed whole or in pieces. Finally, the hippocampus was removed, and the insular cortex was removed or thermally destroyed by low-power (4–5 W) electrocoagulation. MH is a less invasive technique that includes a removal procedure and a disconnection step using the peri-insular technique. The detailed surgical procedure of MH was as follows: (i) the patient was placed in a lateral position, and a craniotomy was performed with a bone flap in the frontotemporal parietal region; the bone flap was 3 cm from the midline and was flush with the temporal base; (ii) the full lateral fissure was opened, and the arteries supplying the anterior temporal lobe and frontal lobe were managed; only 1–2 arteries supplying the parietal lobe and posterior temporal occipital lobe were preserved; (iii) the temporal lobe was removed or reserved dependent on whether the sylvian fissure was atrophied; (iv) the frontal tectum of the insular lobe was removed; (v) the peri-insular technique was used to enter the lateral ventricle, and the frontal, temporal, parietal and occipital fibre connections with the thalamus were disconnected; (vi) the corpus callosum was disconnected in all the sections; and (vii) insular cortex removal or electrocoagulation (4–5 W) was performed. [Figure 2](#) shows the CT and MRI scans of two patients with SWS who underwent FR and HS (MH).

During the operation, the duration of surgery, intraoperative blood loss, and blood transfusion volume were recorded. Additionally, repeated CT scans were obtained in a timely manner after surgery to confirm the management of bleeding. Postoperative MRI was also carried out 3 months after surgery to confirm the resected area. Patients with subtotal removal of the diseased area (lesions involving the eloquent areas) or whose postoperative MRI suggested incomplete resection of lesions were considered as receiving incomplete resection.

Follow-up and surgical outcomes

Surgical patient outcomes were analysed at the 2-year follow-up. The seizure outcomes were assessed according to the Engel Epilepsy Surgery Outcome Scale as follows: Class I, free of disabling seizures (seizure-free status); Class II, infrequent disabling

seizures; Class III, notable improvement; and Class IV, no notable improvement.³² Engel Class I was considered a favourable seizure outcome. The cognitive function and motor function outcomes were assessed using the Denver Developmental Screening Test-II, Wechsler Children Intelligence Scale-IV, Wechsler Adult Intelligence Scale-IV and neurological examination as described above.^{27,33,34} Patients with normal function were considered as having favourable outcomes. Seizure, hemiparesis, and cognition domains of the neurologic score were also assessed as secondary outcomes to determine changes from baseline to follow-up. Improvement, no change or deterioration were classified as improved (decreased), stable (unchanged) or worsened (increased) between the first and last neurologic score.³⁵ Postoperative complications were also recorded.

Statistical analysis

Continuous variables are presented as means and standard deviation (SD). The Shapiro-Wilk test, Kolmogorov-Smirnov test and Levene's test were used to explore the distributions and variance and to further choose appropriate statistical tests. The analysis of differences between the continuous variables from two independent samples or two paired samples was performed using the two independent-sample Student's *t*-test, two paired-sample Student's *t*-test or the rank-sum test (Mann-Whitney U-test or Wilcoxon test), as appropriate. Categorical variables were reported as numbers and percentages. χ^2 test (Pearson's or Fisher's exact) was applied to explore differences between two categorical variables. Pearson's or Spearman's correlation analysis was performed to explore the correlation between two continuous variables. Additionally, this study included an analysis of potential correlations among the characteristics of all patients with SWS. The ϕ -coefficient was used to explore the correlation between two binary variables, such as the sides of facial and leptomenigeal angiomas.

Furthermore, univariable logistic regression analyses were used to identify potential influential factors of cognitive decline for all patients with SWS as well as the factors associated with seizure outcomes for the surgical patients (due to heterogeneity, the FR group and HS groups were analysed separately, and use of the AH or MH technique was included as a factor in the HS group). Factors with $p < 0.10$ were then entered into the multivariable analyses (backward fashion) to adjust for confounding effects of other variables included in the multiple logistic regression. After multivariable analyses, the adjusted odds ratio (aOR) value, its 95% confidence interval (95% CI) and p -values of all independent influential factors were provided. Factors with an aOR value > 1 were considered to be promoting factors. The area under the curve as well as the Youden index were determined using receiver operating characteristic curves to identify an appropriate cut-off for continuous variables (e.g. age), which were then stratified into categorical variables and then entered into logistic analyses.

In the present study, all statistical tests were two-tailed, and the significance level was set to $\alpha = 0.05$. A p -value < 0.05 was considered statistically significant. All statistical analyses were performed using the Statistical Product and Service Solutions (SPSS) software package (version 26; IBM).

Data availability

The data that support the findings of this study are included in the article/[supplementary material](#).

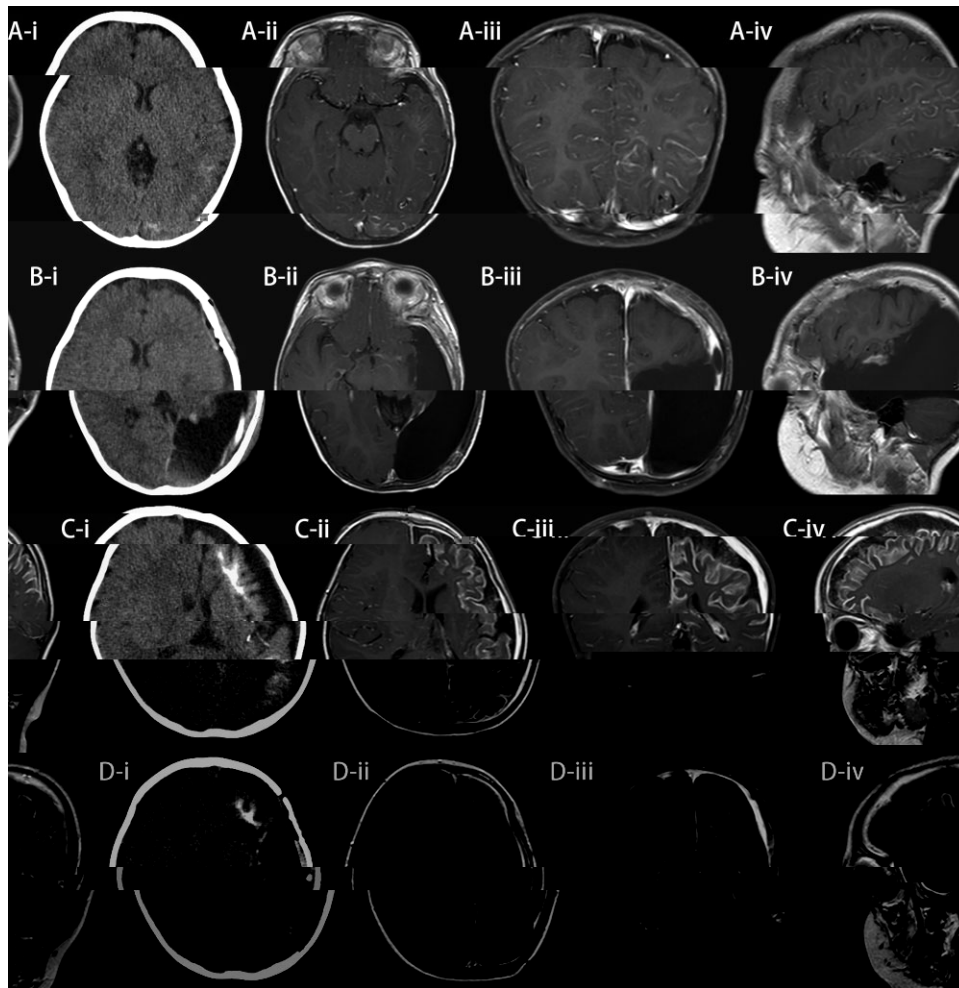


Figure 2 Pre- and postoperative CT and MRI of two patients with SWS who underwent multilobe resection. (A and B: left temporal-parietal-occipital resection) and hemisphere surgery (C and D: left MH). [A(i)] Preoperative CT (axial image); [A(ii)] preoperative MRI (enhanced T₁-weighted image, axial image); [A(iii)] preoperative MRI (enhanced T₁-weighted image, coronal image); [A(iv)] preoperative MRI (enhanced T₁-weighted image, sagittal image); [B(i)] postoperative CT (axial image); [B(ii)] postoperative MRI (enhanced T₁-weighted image, axial image); [B(iii)] preoperative MRI (enhanced T₁-weighted image, coronal image); [B(iv)] postoperative MRI (enhanced T₁-weighted image, sagittal image); [C(i)] preoperative CT (axial image); [C(ii)] preoperative MRI (enhanced T₁-weighted image, axial image); [C(iii)] preoperative MRI (enhanced T₁-weighted image, coronal image); [C(iv)]: preoperative MRI (enhanced T₁-weighted image, sagittal image); [D(i)] postoperative CT (axial image); [D(ii)] postoperative MRI (enhanced T₁-weighted image, axial image); [D(iii)] postoperative MRI (enhanced T₁-weighted image, coronal image); [D(iv)] postoperative MRI (enhanced T₁-weighted image, sagittal image).

Results

Baseline characteristics of the patients

A total of 136 patients were diagnosed with SWS and epilepsy within the enrollment period. After excluding four patients without written informed consent, 132 patients were included in the analyses of SWS characteristics. Among these patients, 40 did not undergo epilepsy surgery (17 did not have refractory epilepsy, 14 had bilateral involvement and nine refused surgery), and two surgical patients did not complete the entire 2-year follow-up. The remaining 90 surgical patients were entered into the analyses of outcomes and factors influencing surgery. For two surgical patients who did not complete the entire 2-year follow-up (could not be contacted), both were seizure-free at the last follow-up (1-year), and no known mortality, morbidity or complications occurred. The baseline characteristics and treatments are shown in [Table 1](#).

Sixty-eight (51.51%) of all included patients with SWS ($n = 132$) were male. The mean age at first seizure onset was 0.97 ± 2.04 (mean \pm SD) years, and 76.52% of the patients had their first epileptic seizures in their first year of life. The most common seizure type was focal seizure (61.36%), which mainly included focal motor seizure (50.76%) and focal to bilateral tonic-clonic seizure (33.33%). Sixty-three (47.73%) patients had generalized seizures, most of whom had generalized tonic-clonic seizures (26.52%). Additionally, 13 (9.85%) and six (4.55%) patients had a history of status epilepticus and refractory status epilepticus, respectively. A total of 126 (95.45%), 78 (59.09%), 58 (43.94%) and 72 (54.55%) patients had facial angiomas, glaucoma, motor defects and cognitive decline, respectively. The mean neurologic scores of the following domains were noted: 2.57 (seizure), 2.05 (hemiparesis) and 1.61 (cognition). Neuroimaging revealed that 96.21%, 69.70% and 65.15% of patients had leptomeningeal angiomas, brain calcification and cortical atrophy, respectively. After analysing the correlations, unilateral or bilateral ($\phi = 0.560$, < 0.001 ; ϕ -coefficient) and left or right sides

Table 1 Baseline characteristics and treatments of all included SWS patients (n = 132)

Surgery type (n)	Sex M/F	Age at first seizure onset (years)	Seizure history (years)	Age at surgery (years)	Facial angiomas Yes/No	Leptomeningeal angiomas Yes/No	Glaucoma Yes/No	Cognitive decline Yes/No	Motor defects Yes/No	Classification I/II/III	Follow-up (years)
All included patients (132)	68/64	0.97 ± 2.04	3.12 ± 4.62	—	126/6	127/5	78/54	72/60	58/74	121/5/6	—
Surgical Patients (90)	48/42	1.11 ± 2.38	3.29 ± 4.71	4.41 ± 5.60	84/6	90/0	53/37	53/37	44/46	84/0/6	4.40 ± 3.33
FR (44)	24/20	1.72 ± 3.28	4.48 ± 5.62	6.21 ± 6.73	40/4	44/0	28/16	16/28	3/41	40/0/4	5.61 ± 3.55
HS (46)	24/22	0.52 ± 0.45*	2.15 ± 3.3	2.69 ± 3.54*	44/2	46/0	25/21	37/9*	41/5*	44/0/2	3.24 ± 2.67*
AH (19)	11/8	0.49 ± 0.42	1.28 ± 0.53	1.77 ± 0.83	19/0	19/0	11/8	15/4	17/2	19/0/0	4.53 ± 3.64
MH (27)	13/14	0.54 ± 0.47	2.76 ± 4.21	3.33 ± 4.49	25/2	27/0	14/13	22/5	24/3	25/0/2	2.33 ± 1.04†

F = female; M = male.

* < 0.01 compared with the FR group (Mann-Whitney U-test, Pearson's χ^2 test or Fisher's exact test, as appropriate).

† < 0.05 compared with the AH group (Mann-Whitney U-test).

($\varphi = 0.709$, < 0.001 ; φ -coefficient) of the facial and leptomeningeal angiomas were positively related. Detailed seizure types, neuroimaging features and neurologic scores of all of the included SWS patients are shown in [Supplementary Table 1](#).

The present study also analysed the influential factors of cognitive decline using univariable ([Supplementary Table 2](#)) and multivariable ([Table 2](#)) analyses. The results revealed that age at onset < 1 year (aOR = 2.903, 95% CI: 1.230–6.514, $\varphi = 0.013$), seizure history ≥ 2 years (aOR = 3.829, 95% CI: 1.810–9.021, $\varphi = 0.008$), brain calcification (aOR = 2.375, 95% CI: 1.396–5.201, $\varphi = 0.021$), left leptomeningeal angiomas (aOR = 2.228, 95% CI: 1.351–32.571, $\varphi = 0.030$) and bilateral leptomeningeal angiomas (aOR = 3.173, 95% CI: 1.970–48.194, $\varphi = 0.013$) were risk factors for cognitive decline.

Of the 90 surgical patients, 72.22% had motor defects or cognitive decline. In total, 48.88% (44) underwent FR, and the remaining 51.11% (46) underwent HS (19 AH and 27 MH). Patients in the HS group had a younger age at first seizure onset ($\varphi = 0.008$; Mann-Whitney U-test), a younger age at surgery ($\varphi = 0.009$; Mann-Whitney U-test), a higher proportion of cognitive decline (< 0.001 ; Pearson's χ^2 test), a higher proportion of motor defects (< 0.001 ; Fisher's exact test) and a shorter follow-up time (< 0.001 ; Mann-Whitney U-test) than the FR group. Regarding the two types of HS, patients in the MH group had a shorter follow-up time ($\varphi = 0.041$; Mann-Whitney U-test) than those in the AH group.

Surgical procedures

Overall, for the 90 surgical patients, the mean duration of surgery was 7.11 ± 1.27 h; the intraoperative blood loss was 640.00 ± 312.16 ml; the blood transfusion volume was 704.43 ± 362.39 ml; and the postoperative hospital stay was 11.80 ± 4.61 days. The HS group had a longer operative time ($\varphi = 0.002$; Mann-Whitney U-test) and a larger blood transfusion volume ($\varphi = 0.032$; Mann-Whitney U-test) than the FR group. Comparison of the AH and MH groups revealed that the MH group had less intraoperative blood loss ($\varphi = 0.048$, Student's t -test) and a shorter postoperative hospital stay ($\varphi = 0.040$, Student's t -test) than the AH group ([Table 3](#)). The postoperative neuropathology of all surgical patients was confirmed as SWS. In total, 53 (58.88%) patients exhibited combined neuropathology as focal cortical dysplasia (FCD), including 27 (50.94%) with FCD Ia, seven (13.21%) with FCD Ib and 19 (35.85%) with FCD IIa based on International League Against Epilepsy 2011 diagnostic methods.³⁶

Surgical outcomes

All 90 included surgical patients completed the 2-year follow-up, and no surgical or late mortality occurred. All patients were alive at last contact. In total, 83.33% of the patients had favourable seizure outcomes (Engel Class I, seizure-free). The seizure-free rates of the patients who underwent FR, HS, AH and MH were 79.55% (35/44), 86.96% (40/46), 89.47% (17/19) and 85.19% (23/27), respectively. Overall, the mean neurologic score in the seizure domain significantly improved (< 0.001 ; Wilcoxon test), and all 90 surgical patients exhibited improvement. Additionally, 44.44% of surgical patients had a favourable outcome in cognitive function. The proportion of favourable cognitive outcomes in the FR group was significantly higher than that in the HS group (68.18% versus 21.74%; < 0.001 ; Pearson's χ^2 test). The mean neurologic score in the cognition domain significantly improved ($\varphi = 0.001$; Wilcoxon test), and 42.22% of patients exhibited improvement. Concerning motor function, a total of 43.33% patients (all FR) had a favourable outcome. All the

HS patients had spastic hemiplegia with the loss of fine motor hand movements, which required rehabilitation. The proportion of favourable motor function in the FR group was significantly higher than that in the HS group (<0.001 ; Wilcoxon test). All the surgical patients could walk autonomously. The mean neurologic score in the hemiparesis domain significantly improved (<0.001 ; Wilcoxon test), and 31.11% of patients exhibited improvement. The detailed surgical procedures, outcomes and postoperative complications are shown in Table 3. The baseline, follow-up and changes in neurologic scores are shown in Table 4.

Overall, five (5.56%) patients had postoperative complications, including infected stitches (two cases, 2.22%; one FR and one AH), intracranial infection (one case, 1.11%; FR), postoperative haemorrhage (one case, 1.11%; AH) and cerebral infarction (one case, 1.11%; MH), which were treated by dressing changes, debridement and antibiotics, craniotomy for the evacuation of haematoma or craniotomy for the resection of the infarct area. These complications were all resolved with good recovery. The proportions of complications in the FR, HS, AH and MH groups were 4.55%, 6.52%, 10.53% and 3.70%, respectively. No significant difference was observed.

Influential factors of seizure outcomes

The present study also conducted analyses for influential factors of seizure outcomes. The univariable analyses are shown in Supplementary Table 3. Factors that showed <0.10 were then entered into multivariable analyses (Table 5). Age at surgery <2 years (aOR = 6.040, 95% CI: 1.444–73.367, $=0.031$) and complete resection (aOR = 11.115, 95% CI: 1.260–98.067, $=0.020$) were positive influential factors of a seizure-free status for FR patients. Age at surgery <2 years (aOR = 15.053, 95% CI: 1.050–215.899, $=0.036$) and infrequent seizures (aOR = 8.426, 95% CI: 1.086–87.442, $=0.042$; monthly versus weekly) were positive influential factors of seizure-free status for HS patients.

Discussion

Characteristics of Sturge-Weber syndrome

As a rare disorder, the clinical presentation of SWS remains unclear.^{5,37} The present study included 132 patients (both surgical

and non-surgical) to analyse characteristics of SWS. Most of the patients (76.52%) in this series experienced their first epileptic seizure within their first year of life. Pascual-Castroviejo *et al.*⁶ reported that 76.6% of their 47 SWS patients experienced their first seizure during the first year after birth, which is consistent with our finding. Previous studies have suggested that the most common epilepsy type among SWS patients was focal, particularly focal motor seizures, which favours secondary generalization (focal to bilateral tonic-clonic seizures), followed by primary generalized seizures, particularly generalized tonic-clonic seizures.^{5,6} The present study revealed that 61.36% of the patients had a history of focal seizures, which were mainly characterized by focal motor seizures and focal to bilateral tonic-clonic seizures. Generalized seizures were observed in 47.73% of the patients, including 26.52% generalized tonic-clonic seizures. Status epilepticus and refractory status epilepticus were observed in 9.85% and 4.55% of the patients in this study, which is also consistent with previous studies.^{5,9} Additionally, 87.12% of the SWS patients had refractory epilepsy in the present study, a proportion higher than that reported in previous studies (30.2–52.0%).^{6,9,37} Notably, as a hospital specializing in epilepsy surgery, a majority of patients came for surgical treatments. This finding is likely related to the higher proportion of patients with refractory epilepsy. Regarding the other clinical presentations, 95.45%, 96.21%, 59.09%, 43.94% and 54.55% of the patients had facial angiomas, leptomeningeal angiomas, glaucoma, motor defects and cognitive decline, respectively. These important presentations have also been previously reported with similar proportions (56–95%, 78–100%, 30–70%, 40–85% and 44–82%; same subjects as noted above).^{5–7,9,13,38–43} The present study applied a neurologic score to assess the clinical severity of SWS.¹⁷ Most of the scores in each domain were higher than those in a previous study. This finding is also related to the increased proportion of surgical patients at our hospital, resulting more clinically severe cases.^{17,26} This neurologic score used cortical volume asymmetry on MRI to assess the correlation with the clinical status, and another study proposed that quantitative EEG could also be helpful in determining neurologic function for SWS.^{17,44} These studies proposed creative tools for the early diagnosis and monitoring of disease progression in SWS, which could represent a further research direction.

Neuroimaging provides critical information for SWS.^{5,20,38} Various MRI sequences have important value for SWS.^{5,20} In this study, enhanced images provide direct presentation of vascular malformations. In addition, FLAIR images provide visualization of the leptomeningeal angioma or dilated superficial and deep cerebral veins, and diffusion-weighted imaging/apparent diffusion coefficient images provide signs of white matter injury.²⁰ Furthermore, several advanced MRI sequences, such as resonance angiography, magnetic resonance venography, susceptibility-weighted imaging, diffusion tensor imaging and functional MRI, can also aid in the clinical diagnosis, evaluation, and research.²⁰ CT scans are superior to MRI for certain peculiar features of SWS, such as subcortical calcification and scalp hyperostosis.⁴⁵ These imaging features provide important information in the choice of optimal treatments.^{5,20,38} Importantly, although it was not observed in this study, some reports have suggested that MRI may be completely negative for SWS during the neonatal period.^{18,46} Nuclear imaging, such as PET or single photon emission computed tomography (SPECT), can also be helpful in evaluating the functional abnormalities and lateralization or localization of the epileptogenic area.^{20,47–50} Multimodality imaging of different imaging technologies [e.g. PET/CT and subtraction ictal SPECT co-registered

Table 2 Multivariable analyses of influential factors of cognitive decline for all included SWS patients ($n = 132$)

Factor	aOR	95%CI	P
Age at onset			
<1 year	2.903	1.230–6.514	0.013*
≥1 year	Contract	—	—
Seizure history			
<2 years	Contract	—	—
≥2 years	3.829	1.810–9.021	0.008**
CT			
No brain calcification	Contract	—	—
Brain calcification	2.375	1.396–5.201	0.021*
MRI			
No LA	Contract	—	—
Left LA	2.228	1.351–32.571	0.030*
Right LA	1.213	0.623–17.301	0.379
Bilateral LA	3.173	1.970–48.194	0.013*

LA = leptomeningeal angioma

* <0.05 (multivariable logistic regression).

** <0.01 (multivariable logistic regression).

Table 3 Surgical procedure, outcomes and postoperative complications of surgical SWS patients (n = 90)

Surgical procedure (n)	FR (44)	HS (46)	AH (19)	MH (27)	All (90)
Duration of surgery (h)	6.63 ± 1.18	7.56 ± 1.19**	7.54 ± 1.12	7.57 ± 1.26	7.11 ± 1.27
Blood loss (ml)	606.82 ± 337.67	671.74 ± 285.76	770.53 ± 284.63	602.22 ± 270.36 [†]	640.00 ± 312.16
Transfusion of blood (ml)	617.89 ± 366.23	787.22 ± 342.41*	886.16 ± 327.54	717.59 ± 335.68	704.43 ± 362.39
Postoperative hospital stays (days)	11.55 ± 4.33	12.48 ± 5.27	15.37 ± 6.29	11.44 ± 4.09 [†]	11.80 ± 4.61
Seizure outcome					
Favourable (Engel Class I/seizure free)	35 (79.55)	40 (86.96)	17 (89.47)	23 (85.19)	75 (83.33)
Unfavourable	9 (20.45)	6 (13.04)	2 (10.53)	4 (14.81)	15 (16.67)
Engel Class II	7 (15.91)	5 (10.87)	2 (10.53)	3 (11.11)	12 (13.33)
Engel Class III	2 (4.55)	1 (2.17)	0 (0.00)	1 (3.70)	3 (3.33)
Cognitive function					
Favourable	30 (68.18)	10 (21.74)**	4 (21.05)	6 (22.22)	40 (44.44)
Unfavourable	14 (31.82)	36 (78.26)	15 (78.95)	21 (77.78)	50 (55.56)
Motor function					
Favourable	39 (88.64)	0 (0.00)**	0 (0.00)	0 (0.00)	39 (43.33)
Unfavourable	5 (11.36)	46 (100.00)	19 (100.00)	27 (100.00)	51 (56.67)
Postoperative complications					
With	2 (4.55)	3 (6.52)	2 (10.53)	1 (3.70)	5 (5.56)
Without	42 (95.45)	43 (93.48)	17 (89.47)	26 (96.30)	85 (94.44)

* < 0.05 compared with the FR group (Pearson's χ^2 test or Mann-Whitney U-test, as appropriate).

** < 0.01 compared with the FR group (Pearson's χ^2 test or Mann-Whitney U-test, as appropriate).

[†] < 0.05 compared with the AH group (Student's *t*-test or Pearson's χ^2 test).

Table 4 Baseline, follow-up, and changes of neurologic score of surgical SWS patients (n = 90)

Neurologic score	Baseline	Follow-up	Improvement	No change	Deterioration
Seizure	3.77 ± 0.43	0.21 ± 0.53*	90 (100.00)	0 (0.00)	0 (0.00)
Cognition	1.74 ± 1.70	1.26 ± 1.32*	38 (42.22)	46 (51.11)	6 (6.67)
Hemiparesis	2.21 ± 1.44	1.87 ± 1.36*	28 (31.11)	53 (58.89)	9 (10.00)

* < 0.01 compared with baseline (Wilcoxon test).

to MRI (SISCOM)] may provide a better solution to overcome the limitations of the independent techniques.^{20,46,49,51}

Furthermore, the present study revealed that patients with unilateral facial angiomas were more likely to have unilateral leptomeningeal angiomas, and unilateral facial and leptomeningeal angiomas were more likely to occur on the same side. Some previous studies on SWS also suggested that brain angiomas are generally associated with facial distribution.^{6,39} This phenomenon might represent the regular distribution pattern of facial and leptomeningeal angiomas. However, evaluation of the distribution of leptomeningeal angiomas by facial representations is not convincing or reliable,⁵ which requires detailed presurgical evaluation, particularly MRI.

Factors that influence cognitive decline

This study also analysed the potential influential factors of cognitive decline for all included SWS patients. Seizure history ≥ 2 years, bilateral leptomeningeal angiomas, age at onset < 1 year, brain calcification and left leptomeningeal angiomas were risk factors for cognitive decline, suggesting that patients with these characteristics were at a higher risk of cognitive decline and should receive timely treatment. Luat *et al.*⁵² and Bourgeois *et al.*¹³ also proposed that age at seizure onset, high seizure frequency and long epilepsy duration were associated with cognitive functions. These findings further demonstrate the importance of early seizure control in preventing the progression of cognitive decline. Brain calcification was observed in 69.70% of patients in this study and was associated with cognitive decline. Pilli *et al.*⁵³ revealed that 66.7% of 15 patients

with SWS had brain calcification. They also suggested that brain calcification was associated with hypometabolism, indicating tissue damage from brain injury.^{5,53} Increased calcified brain volumes may also indicate a risk for earlier epilepsy onset, longer epilepsy duration, and more severe epilepsy, resulting in poorer neurocognitive outcomes, which should be considered.^{20,53,54}

Surgical indications

The main purposes of epilepsy surgery are to stop uncontrollable seizures and prevent motor or cognitive function from further worsening due to seizures.^{13,37} Thus, surgical treatment for SWS patients with refractory epilepsy and motor or cognitive decline is deemed necessary.^{5,19,40} In this study, 59 patients met this indication (6-month AED trial failure); all of them had progressive motor defects or cognitive decline. Additionally, because nearly all patients will develop spastic hemiplegia on the contralateral side of the resected hemisphere, HS is preferred for patients with hemiparesis contrary to the side of the intracranial lesion.⁵⁵⁻⁵⁷ However, the decision to perform surgery for patients without apparent motor defects or cognitive decline should be made cautiously.^{5,46} For 25 patients without motor defects or cognitive decline, a prolonged period (24 months) of AED medication treatment was provided to ensure its refractory nature. Then, the decision to perform surgery was made.

Refractory status epilepticus is a neurological emergency with considerable associated neuronal injury, asphyxia and even mortality.^{24,58,59} Previous studies have suggested that patients with early refractory status epilepticus (before a 6-month AED trial)

and evolving neurodevelopmental deficits should undergo surgery as early as possible to prevent catastrophic epilepsy and neurocognitive decline.^{5,13} In this study, six patients met the surgical indication of having refractory status epilepticus, and all of them had both motor defects and cognitive decline, including two patients with refractory status epilepticus in our hospital who accepted emergency AH. Thus, we suggest that SWS patients with refractory status epilepticus should undergo epilepsy surgery as soon as possible.

Additionally, several studies have suggested that some SWS patients showed a pattern of seizure clustering followed by a prolonged seizure-free period,^{26,60,61} and this pattern did not increase the risk of developmental and motor disability.²⁶ Thus, these patients represent ideal candidates for surgery.²⁶ In the present study, 14 patients (10.61%) exhibited this pattern, which was recognized as non-refractory epilepsy, and were excluded from surgery. However, this pattern was observed less often in this series compared with previous studies (22–50%).^{26,60,61} This finding is potentially related to the fact that our hospital specializes in epilepsy surgery; thus, fewer non-refractory epilepsy patients are included in this study. The other 17 surgical patients with seizure clustering who did not exhibit this pattern all showed motor defects or cognitive decline, and surgery was needed. For SWS patients with only seizure clustering without motor defects or cognitive decline, intractability is difficult to demonstrate when seizures with this pattern do not occur for months to years.²⁶ Thus, assessments of neurological function, seizure types, history, and AED trails should be conducted carefully for patients with seizure clustering to determine whether and when to choose surgical treatments.

Surgical outcomes

Epilepsy surgery has been recognized as the first line of treatment for SWS patients.^{5,62} Some studies have reported its surgical outcomes.^{5,11–15,62,63} However, the sample size of most previous reports was small, and limited analyses are available. In the present study, we included 90 surgical patients to present a complete picture of epilepsy surgery for SWS. To the best of our knowledge, the present study is the largest on surgical SWS patients.^{5,9}

HS is universally considered as the first choice for unilateral SWS patients.^{5,9,43} In the present study, the postoperative seizure-free rate of the HS group was 86.96%. Previous studies of HS for SWS also showed a good seizure-free rate of 57–100%.^{5,11–15,55,57,63–65}

Additionally, 43.48% of the HS group improved in the cognition domain. Several previous studies also reported significant improvements in cognitive function and development.^{5,13,14} Regarding the safety of HS, 6.52% of these patients developed postoperative complications, which were all resolved. Furthermore, only 8.70% and 15.22% of the patients showed deteriorations in cognition and hemiparesis, respectively. These findings together with those of previous studies indicate that HS was safe for patients with SWS.^{5,13} HS is an established and widely practiced surgery.^{12,55,57,66} Leptomeningeal angiomas make vascular management more challenging. However, apart from the increased blood loss and longer operative time, current findings suggested that performing HS on SWS patients did not lead to significantly higher intraoperative risks than other epileptic disorders.^{5,12,13,55,57,66}

Two types of HS (AH and MH) were performed in this study. Several modifications have been implemented to make HS surgeries less invasive⁶⁷ and to decrease blood loss.⁵ MH was achieved as a modification of AH and was performed later in this series. This study suggested that patients who underwent MH had less intraoperative blood loss and shorter postoperative hospital stays than those who underwent AH, suggesting that MH is a less invasive and safer technique. Furthermore, previous studies including SWS patients who underwent different modifications of HS showed no significant difference in the outcomes.^{5,14,64} The present study also revealed no significant differences in the seizure, cognitive, or motor outcomes between the AH and MH groups. Thus, MH can yield similar outcomes and can be less invasive and safer than traditional AH. However, few studies have directly compared the different approaches of HS for SWS, warranting future investigation.

FR was performed in 44 patients in this study when the epileptic area involved only the focal area or several brain lobes. FR was less reported than HS in previous studies on SWS.^{13,60,64,68} Previous studies have suggested a seizure-free rate of 50–64% for SWS patients who underwent FR, which was less than that for patients who underwent HS.^{13,60,64,68} Additionally, some studies proposed that FR could only control seizures for a limited period.^{46,69} In the present study, 79.55% of FR patients were seizure-free, and this proportion was slightly higher than that in previous studies.^{13,60,64,68} Although this seizure-free rate was lower than that of patients in the HS group in the present study, the difference did not reach statistical significance. The FR group had a significantly higher proportion of favourable cognitive and motor outcomes than the HS group. However, this difference was related to a lower proportion of baseline cognitive and motor defects in the FR group, reflecting a tendency to choose patients without cognitive and motor defects to perform FR. FR has a certain advantage as a lower surgical risk.^{13,64,70} The present study revealed a significantly shorter operative time and fewer blood transfusions in the FR group than in the HS group. Additionally, the proportion of patients who showed deterioration in the cognition and hemiparesis domains were both only 4.55%, suggesting good safety with regard to neurological protection.^{5,64} Few studies have applied two-stage or three-stage surgery for intracranial EEG monitoring before FR (or accompanied by postoperative monitoring) of the epileptogenic focus.^{71,72} An obvious advantage is that it can be helpful to localize the epileptic area and ensure complete resection of epileptogenic tissue.^{71,72} However, most current studies and the present study only conducted a single-stage surgery to reduce the risk of infarction and bleeding.^{5,13} Further studies should weigh the added risks of multiple surgeries and longer hospital stays against the potential benefit to reach a better choice.⁷²

Table 5 Multivariable analyses of influential factors of the seizure outcome for surgical SWS patients (n = 90)

Factor	aOR	95% CI	P
Focal resection			
Age at surgery			
<2 years	6.040	1.444–73.367	0.031*
≥2 years	Contract	—	—
Full resection			
Yes	11.115	1.260–98.067	0.020*
No	Contract	—	—
Hemisphere surgery			
Age at surgery			
<2 years	15.053	1.050–215.899	0.036*
≥2 years	Contract	—	—
Seizure frequency			
Weekly	Contract	—	—
Monthly	8.426	1.086–87.442	0.042*

* <0.05 (multivariable logistic regression).

This study applied a routine AED schedule in which patients who took one type of AED began trials on the discontinuation 2 years after they were seizure free and without EEG interictal discharge; for patients undergoing FR with one type of AED who were seizure free but still had EEG interictal discharge, the trials on the discontinuation were delayed to 4–5 years. For patients who took more than one type of AED, the discontinuation of one type of AED began 1 year after they were seizure free.^{73,74} Five-year follow-up data were available for 27 patients in this series, including 77.78% who patients remained seizure-free and 59.26% patients who discontinued AEDs. These findings are similar to those reported by Bianchi *et al.*⁵ The present study only focused on analysing the 2-year outcome because insufficient data were available to analyse a longer follow-up. Thus, further study with a larger series and longer follow periods is needed to explore the long-term outcomes and AED schedule.

Issues related to surgical treatments

Some studies have suggested that low-dose aspirin combined with AEDs in SWS patients could reduce seizure frequency, and proposed hypothesis that aspirin may delay seizure onset.^{75,76} A study by Lance *et al.*³⁵ indicated that the majority of SWS patients on aspirin experienced reasonable seizure, hemiparesis, vision, and cognitive outcomes. However, it should be noted that aspirin use might cause side effects and increased risk of bleeding during surgery.⁷⁷ A previous study showed that 39% of SWS patients with aspirin reported a history of complications.⁷⁷ The standard treatments for SWS in our hospital did not include the use of aspirin. Therefore, the surgical patients in this study did not have this concern. For SWS patients on aspirin, additional studies are needed to explore the balance between the potential benefits and the influence of complications and surgical risks.

Notably, several studies have proposed that early imaging frequently underdiagnoses the extent of brain involvement in SWS patients, particularly in those aged <1 year.^{5,38} Patients with bilateral involvement might only present unilaterally in neuroimaging.^{5,6,63} In the present study, we intraoperatively found that 18.18% FR patients had larger involved areas than that noted during preoperative neuroimaging. Thus, we appropriately adjusted their resection area. For HS patients, we could not confirm whether they had bilateral lesions because only unilateral craniotomy was performed. However, for the HS patients who were not seizure-free after surgery, the possibility of bilateral involvement cannot be excluded.

The postoperative neuropathology of this study and previous studies suggests that FCDs are frequently combined in SWS patients.^{10,38,78,79} The current classification of FCD indicates that SWS should be type IIIc.^{38,71,78} Because FCD is frequent in SWS patients with refractory epilepsy, several studies have suggested that FCD might play an important epileptogenic role, and complete resection of the associated FCD should be considered to achieve seizure control.^{10,78} Notably, most cortical malformations are not readily detected on MRI.^{10,38} No patient with combined neuropathological cortical malformation was identified by neuroimaging in this study, whereas Pinto *et al.*³⁸ also suggested that no MRI abnormalities corresponded directly with the pathological findings of FCD, except in one patient with polymicrogyria. The relationship between SWS and combined neuropathology deserves further exploration.

Influential factors of seizure outcomes

Analysis of influential factors may help preoperative counseling and select optimal candidates.^{13,80} Factors related to timing were previously found to play an important role in influencing surgical outcomes.¹³ However, current evidence is lacking concerning surgical timing for SWS patients with refractory epilepsy.^{5,40} The present study suggested that age at surgery <2 years is a positive factor for seizure outcome in both the FR group and HS group, whereas the other cutoffs and different age groups showed no other significant differences. Additionally, a longer seizure history (≥ 2 years) was also identified as a risk factor for cognitive decline in the characteristics analysis, suggesting that earlier treatments should be administered. Previous studies also suggest that earlier surgical treatment results in excellent seizure outcomes and less developmental deterioration.^{13,14,81} Bourgeois *et al.*¹³ revealed that surgical SWS patients who achieved improvement in their developmental status were younger at the time of surgery than those who did not. Given the plasticity in the developing brain, surgery performed early may allow reorganization and preservation of neurological function, which we also observed in the present study as children experienced gradual recovery in motor and cognitive function.^{82,83} The present study also revealed that a younger age at surgery was positively associated with a better improvement in neurologic scores of the cognitive domain ($r = 0.471$, $P < 0.001$; Spearman's correlation) and hemiparesis ($r = 0.274$, $P = 0.009$; Spearman's correlation). Therefore, this study suggests that the timing of surgery should be early for SWS patients with surgical indications to achieve better surgical outcomes and protect cognitive function. However, this single-centre study can only reflect the experience of our centre, and the limited case numbers in different age groups may also influence the results. Thus, the suggestion of surgical timing <2 years of age may be not applicable to every centre. It should be noted that, although it was not observed in this study, previous studies have indicated that lower surgical ages (<1 year or <2 years) and body weight (<11 kg) could increase the surgical and anesthetic risk for epilepsy surgery, especially HS.^{12,66,84–86} For SWS patients, the large amount of intraoperative blood loss and the unreliable neuroimaging of young children (especially <1-year-old) can also be challenging. In clinical practice, health providers should consider the risks of surgery for young children and choose the optimal time for surgery. To confirm the suggestion of early surgery and explore the optimal surgical timing, further studies from international multi-centres with larger series are needed.

Completeness of resection was also found to affect seizure outcome and developmental improvement in several previous studies.^{5,13,64} The present study also revealed that complete resection of lesions contributed to favourable seizure outcomes in the FR group, suggesting that efforts should be made to achieve complete resection of the epileptic area. This study also suggested that infrequent seizures (monthly versus weekly) were a positive factor for seizure outcome in the HS group, a finding that has not been reported previously. Several studies have also proposed that, with generalized tonic-clonic seizures, male sex, young age at seizure onset and type I SWS might be negative prognostic factors for seizure outcomes,^{43,52,63} findings that were not observed in the present study. However, given the limited number of cases, more research efforts and cooperation are still required.

Limitations

First, retrospective analysis has inherent limitations, such as poor control factors and potential biases. Second, a featured epilepsy

surgery hospital might introduce selection bias. Third, several advanced imaging technologies, such as susceptibility-weighted imaging, PET, diffusion tensor imaging and multimodality imaging, were not routinely used. Adequate use of these technologies may help to objectively evaluate the adequacy of the disconnection and may predict the postoperative outcomes.^{87,88} Fourth, the Denver Developmental Screening Test-II is a screening tool, which is not completely comparable with other IQ tests (Wechsler Children Intelligence Scale-IV and Wechsler Adult Intelligence Scale-IV) when evaluating cognitive function.²⁷ Therefore, we analysed these assessments separately. Fifth, the present study only reported surgical treatment without aspirin, limiting further comparisons. Finally, a multicentre study would better identify variables that can predict patient outcomes. However, our hospital is responsible for a large proportion of the treatment for SWS patients in our country, possibly influencing the balance of the sample size for a domestic multicentre study. Future international cooperation on SWS can aid in further understanding this rare disorder.^{20,40}

Conclusions

Epilepsy surgery showed good postoperative seizure, cognitive, and motor functional outcomes and acceptable safety for patients with epilepsy and SWS. MH is a less invasive and safer type of HS than traditional AH with similar surgical outcomes. Early surgery might help achieve better seizure outcomes and cognitive protection, while the risk of surgery for young children should also be considered.

Funding

This work was supported by the National Key Research and Development Program of China (2018YFC2000700, 2016YFC0105900) and the National Natural Science Foundation of China (81790654).

Competing interests

The authors report no competing interests.

Supplementary material

Supplementary material is available at [Brain](#) online.

References

- Rihani HT, Dalvin LA, Hodge DO, Pulido JS. Incidence of Sturge-Weber syndrome and associated ocular involvement in Olmsted County, Minnesota, United States. *Genet Epidemiol*. 2020;41(2):108–124.
- Lian CG, Sholl LM, Zakka LR, et al. Novel genetic mutations in a sporadic port-wine stain. *JAMA Dermatol*. 2014;150(12):1336–1340.
- Tan W, Chernova M, Gao L, et al. Sustained activation of c-Jun N-terminal and extracellular signal-regulated kinases in port-wine stain blood vessels. *JAMA Dermatol*. 2014;71(5):964–968.
- Shirley MD, Tang H, Gallione CJ, et al. Sturge-Weber syndrome and port-wine stains caused by somatic mutation in GNAQ. *Eur J Med Genet*. 2013;368(21):1971–1979.
- Bianchi F, Auricchio AM, Battaglia DI, Chieffo DRP, Massimi L. Sturge-Weber syndrome: An update on the relevant issues for neurosurgeons. *Curr Opin Neurol*. 2020;36(10):2553–2570.
- Pascual-Castroviejo I, Pascual-Pascual SI, Velazquez-Fragua R, Víaño J. Sturge-Weber syndrome: Study of 55 patients. *Curr Opin Neurol*. 2008;35(3):301–307.
- Javaid U, Ali MH, Jamal S, Butt NH. Pathophysiology, diagnosis, and management of glaucoma associated with Sturge-Weber syndrome. *Int J Ophthalmol*. 2018;38(1):409–416.
- Jagtap S, Srinivas G, Harsha KJ, Radhakrishnan N, Radhakrishnan A. Sturge-Weber syndrome: Clinical spectrum, disease course, and outcome of 30 patients. *J Child Neurol*. 2013;28(6):725–731.
- Sudarsanam A, Ardern-Holmes SL. Sturge-Weber syndrome: From the past to the present. *Eur J Paediatr Neurol*. 2014;18(3):257–266.
- Maton B, Krsek P, Jayakar P, et al. Medically intractable epilepsy in Sturge-Weber syndrome is associated with cortical malformation: Implications for surgical therapy. *Epilepsia*. 2010;51(2):257–267.
- Alkonyi B, Chugani HT, Karia S, Behen ME, Juhász C. Clinical outcomes in bilateral Sturge-Weber syndrome. *Epilepsia*. 2011;44(6):443–449.
- Basheer SN, Connolly MB, Lautzenhiser A, Sherman EM, Hendson G, Steinbok P. Hemispheric surgery in children with refractory epilepsy: Seizure outcome, complications, and adaptive function. *Epilepsia*. 2007;48(1):133–140.
- Bourgeois M, Crimmins DW, de Oliveira RS, et al. Surgical treatment of epilepsy in Sturge-Weber syndrome in children. *J Child Neurol*. 2007;106(1 Suppl):20–28.
- Kossoff EH, Buck C, Freeman JM. Outcomes of 32 hemispherectomies for Sturge-Weber syndrome worldwide. *Epilepsia*. 2002;59(11):1735–1738.
- Steinbok P, Gan PY, Connolly MB, et al. Epilepsy surgery in the first 3 years of life: A Canadian survey. *Epilepsia*. 2009;50(6):1442–1449.
- Roach ES. Diagnosis and management of neurocutaneous syndromes. *Semin Dermatol*. 1988;8(1):83–96.
- Kelley TM, Hatfield LA, Lin DD, Comi AM. Quantitative analysis of cerebral cortical atrophy and correlation with clinical severity in unilateral Sturge-Weber syndrome. *J Child Neurol*. 2005;20(11):867–870.
- Comi AM. Presentation, diagnosis, pathophysiology, and treatment of the neurological features of Sturge-Weber syndrome. *Epilepsia*. 2011;17(4):179–184.
- Lo W, Marchuk DA, Ball KL, et al. Updates and future horizons on the understanding, diagnosis, and treatment of Sturge-Weber syndrome brain involvement. *Dev Med Child Neurol*. 2012;54(3):214–223.
- De la Torre AJ, Luat AF, Juhász C, et al. A multidisciplinary consensus for clinical care and research needs for Sturge-Weber syndrome. *Epilepsia*. 2018;84:11–20.
- Kwan P, Arzimanoglou A, Berg AT, et al. Definition of drug resistant epilepsy: Consensus proposal by the ad hoc Task Force of the ILAE Commission on Therapeutic Strategies. *Epilepsia*. 2010;51(6):1069–1077.
- Trinka E, Cock H, Hesdorffer D, et al. A definition and classification of status epilepticus—report of the ILAE Task Force on Classification of Status Epilepticus. *Epilepsia*. 2015;56(10):1515–1523.
- Brophy GM, Bell R, Claassen J, et al. Guidelines for the evaluation and management of status epilepticus. *Curr Opin Neurol*. 2012;17(1):3–23.
- Vasquez A, Farias-Moeller R, Tatum W. Pediatric refractory and super-refractory status epilepticus. *Childs Nerv Syst*. 2019;68:62–71.

25. Fisher RS, Cross JH, D'Souza C, et al. Instruction manual for the ILAE 2017 operational classification of seizure types. *Epilepsia*. 2017;58(4):531–542.
26. Kossoff EH, Ferenc L, Comi AM. An infantile-onset, severe, yet sporadic seizure pattern is common in Sturge-Weber syndrome. *Epilepsia*. 2009;50(9):2154–2157.
27. Lipkin PH, Macias MM. Promoting optimal development: Identifying infants and young children with developmental disorders through developmental surveillance and screening. *Paediatr Child Health*. 2020;145(1):e20193449.
28. Na SD, Burns TG. Wechsler intelligence scale for children-V: Test review. *Arch Clin Neurol*. 2016;5(2):156–160.
29. Wisdom NM, Mignogna J, Collins RL. Variability in Wechsler adult intelligence Scale-IV subtest performance across age. *Arch Clin Neurol*. 2012;27(4):389–397.
30. Wang S, Wang X, Zhao M, et al. Long-term efficacy and cognitive effects of voltage-based deep brain stimulation for drug-resistant essential tremor. *Cerebellum*. 2020;19(4):105940.
31. Wang S, Zhao M, Li T, et al. Long-term efficacy and cognitive effects of bilateral hippocampal deep brain stimulation in patients with drug-resistant temporal lobe epilepsy. *Epilepsia*. 2021;42(1):225–233.
32. Baud MO, Perneger T, Rác A, et al. European trends in epilepsy surgery. *Epilepsia*. 2018;91(2):e96–e106.
33. Skirrow C, Cross JH, Owens R, et al. Determinants of IQ outcome after focal epilepsy surgery in childhood: A longitudinal case-control neuroimaging study. *Epilepsia*. 2019;60(5):872–884.
34. Van Schooneveld MM, Braun KP. Cognitive outcome after epilepsy surgery in children. *Brain*. 2013;35(8):721–729.
35. Lance EI, Sreenivasan AK, Zabel TA, Kossoff EH, Comi AM. Aspirin use in Sturge-Weber syndrome: Side effects and clinical outcomes. *J Child Neurol*. 2013;28(2):213–218.
36. Blümcke I, Thom M, Aronica E, et al. The clinicopathologic spectrum of focal cortical dysplasias: A consensus classification proposed by an ad hoc Task Force of the ILAE Diagnostic Methods Commission. *Epilepsia*. 2011;52(1):158–174.
37. Luat AF, Juhász C, Loeb JA, et al. Neurological complications of Sturge-Weber syndrome: Current status and unmet needs. *Epilepsia*. 2019;98:31–38.
38. Pinto AL, Chen L, Friedman R, et al. Sturge-Weber syndrome: Brain magnetic resonance imaging and neuropathology findings. *Epilepsia*. 2016;58:25–30.
39. Fogarasi A, Loddenkemper T, Mellado C, et al. Sturge-Weber syndrome: Clinical and radiological correlates in 86 patients. *Int J Radiat Oncol Biol Phys*. 2013;66(1–2):53–57.
40. Cho S, Maharathi B, Ball KL, Loeb JA, Pevsner J. Sturge-Weber syndrome patient registry: Delayed diagnosis and poor seizure control. *J Child Neurol*. 2019;215:158–163.e6.
41. Silverstein M, Salvin J. Ocular manifestations of Sturge-Weber syndrome. *Clin Exp Neurol*. 2019;30(5):301–305.
42. Day AM, McCulloch CE, Hammill AM, et al. Physical and family history variables associated with neurological and cognitive development in Sturge-Weber syndrome. *Epilepsia*. 2019;96:30–36.
43. Harmon KA, Day AM, Hammill AM, Pinto AL, McCulloch CE, Comi AM. Quality of life in children with Sturge-Weber syndrome. *Epilepsia*. 2019;101:26–32.
44. Hatfield LA, Crone NE, Kossoff EH, et al. Quantitative EEG asymmetry correlates with clinical severity in unilateral Sturge-Weber syndrome. *Epilepsia*. 2007;48(1):191–195.
45. Ragupathi S, Reddy AK, Jayamohan AE, Lakshmanan PM. Sturge-Weber syndrome: CT and MRI illustrations. *BMJ Case Rep*. 2014;2014:bcr2014205743.
46. Comi AM. Advances in Sturge-Weber syndrome. *Clin Neurol Neurosurg*. 2006;19(2):124–128.
47. Juhász C, Haacke EM, Hu J, et al. Multimodality imaging of cortical and white matter abnormalities in Sturge-Weber syndrome. *AJNR*. 2007;28(5):900–906.
48. Lee JS, Asano E, Muzik O, et al. Sturge-Weber syndrome: Correlation between clinical course and FDG PET findings. *Epilepsia*. 2001;57(2):189–195.
49. Namer JJ, Battaglia F, Hirsch E, Constantinesco A, Marescaux C. Subtraction ictal SPECT co-registered to MRI (SISCOM) in Sturge-Weber syndrome. *Clin Neurol Neurosurg*. 2005;30(1):39–40.
50. Juhász C, Hu J, Xuan Y, Chugani HT. Imaging increased glutamate in children with Sturge-Weber syndrome: Association with epilepsy severity. *Epilepsia*. 2016;122:66–72.
51. Oguz KK, Senturk S, Ozturk A, Anlar B, Topcu M, Cila A. Impact of recent seizures on cerebral blood flow in patients with sturge-weber syndrome: Study of 2 cases. *J Child Neurol*. 2007;22(5):617–620.
52. Luat AF, Behen ME, Chugani HT, Juhász C. Cognitive and motor outcomes in children with unilateral Sturge-Weber syndrome: Effect of age at seizure onset and side of brain involvement. *Epilepsia*. 2018;80:202–207.
53. Pilli VK, Behen ME, Hu J, et al. Clinical and metabolic correlates of cerebral calcifications in Sturge-Weber syndrome. *Dev Med Child Neurol*. 2017;59(9):952–958.
54. Wu J, Tarabishy B, Hu J, et al. Cortical calcification in Sturge-Weber Syndrome on MRI-SWI: Relation to brain perfusion status and seizure severity. *J Magn Reson Imaging*. 2011;34(4):791–798.
55. Vining EP, Freeman JM, Pillas DJ, et al. Why would you remove half a brain? The outcome of 58 children after hemispherectomy—the Johns Hopkins experience: 1968 to 1996. *Epilepsia*. 1997;100(2 Pt 1):163–171.
56. van Empelen R, Jennekens-Schinkel A, Buskens E, Helders PJ, van Nieuwenhuizen O. Functional consequences of hemispherectomy. *Brain*. 2004;127(Pt 9):2071–2079.
57. Kossoff EH, Vining EP, Pillas DJ, et al. Hemispherectomy for intractable unihemispheric epilepsy etiology vs outcome. *Epilepsia*. 2003;61(7):887–890.
58. Hawkes MA, English SW, Mandrekar JN, Rabinstein AA, Hocker S. Causes of death in status Epilepticus. *Crit Care Med*. 2019;47(9):1226–1231.
59. Betjemann JP, Lowenstein DH. Status epilepticus in adults. *Lancet*. 2015;14(6):615–624.
60. Kramer U, Kahana E, Shorer Z, Ben-Zeev B. Outcome of infants with unilateral Sturge-Weber syndrome and early onset seizures. *Dev Med Child Neurol*. 2000;42(11):756–759.
61. Fogarasi A, Janszky J, Faveret E, Pieper T, Tuxhorn I. A detailed analysis of frontal lobe seizure semiology in children younger than 7 years. *Epilepsia*. 2001;42(1):80–85.
62. Sugano H, Nakanishi H, Nakajima M, et al. Posterior quadrant disconnection surgery for Sturge-Weber syndrome. *Epilepsia*. 2014;55(5):683–689.
63. de Palma L, Pietrafusa N, Gozzo F, et al. Outcome after hemispherotomy in patients with intractable epilepsy: Comparison of techniques in the Italian experience. *Epilepsia*. 2019;93:22–28.
64. Arzimanoglou AA, Andermann F, Aicardi J, et al. Sturge-Weber syndrome: Indications and results of surgery in 20 patients. *Epilepsia*. 2000;55(10):1472–1479.
65. Schramm J, Kuczaty S, Sassen R, Elger CE, von Lehe M. Pediatric functional hemispherectomy: Outcome in 92 patients. *Acta Neurol Scand*. 2012;154(11):2017–2028.

66. McGovern RA, A NVM, Jehi L, et al. Hemispherectomy in adults and adolescents: Seizure and functional outcomes in 47 patients. *Epilepsia*. 2019;60(12):2416–2427.
67. Young CC, Williams JR, Feroze AH, et al. Pediatric functional hemispherectomy: Operative techniques and complication avoidance. *Childs Nerv Syst*. 2020;48(4):E9.
68. Siri L, Giordano L, Accorsi P, et al. Clinical features of Sturge-Weber syndrome without facial nevus: Five novel cases. *Epilepsia*. 2013;17(1):91–96.
69. Cunha e Sá M, Barroso CP, Caldas MC, Edvinsson L, Gulbenkian S. Innervation pattern of malformative cortical vessels in Sturge-Weber disease: An histochemical, immunohistochemical, and ultrastructural study. *Acta Neuropathol*. 1997;41(4):872–876; discussion 876–7.
70. Barbagallo M, Ruggieri M, Incorpora G, et al. Infantile spasms in the setting of Sturge-Weber syndrome. *Clin Neurophysiol*. 2009;25(1):111–118.
71. Murakami N, Morioka T, Suzuki SO, et al. Focal cortical dysplasia type IIa underlying epileptogenesis in patients with epilepsy associated with Sturge-Weber syndrome. *Epilepsia*. 2012;53(11):e184–e188.
72. Shekhtman Y, Kim I, Riviello JJ, Jr., Milla SS, Weiner HL. Focal resection of leptomeningeal angioma in a rare case of Sturge-Weber syndrome without facial nevus. *Childs Nerv Syst*. 2013;49(2):99–104.
73. Schmeiser B, Steinhoff BJ, Schulze-Bonhage A. Does early postoperative drug regimen impact seizure control in patients undergoing temporal lobe resections? *J Child Neurol*. 2018;265(3):500–509.
74. Schachter SC. Determining when to stop antiepileptic drug treatment. *Clin Neurophysiol*. 2018;31(2):211–215.
75. Day AM, Hammill AM, Juhász C, et al. Hypothesis: Presymptomatic treatment of Sturge-Weber syndrome with aspirin and antiepileptic drugs may delay seizure onset. *Epilepsia*. 2019;90:8–12.
76. Triana Junco PE, Sánchez-Carpintero I, López-Gutiérrez JC. Preventive treatment with oral sirolimus and aspirin in a newborn with severe Sturge-Weber syndrome. *Epilepsia*. 2019;36(4):524–527.
77. Bay MJ, Kossoff EH, Lehmann CU, Zabel TA, Comi AM. Survey of aspirin use in Sturge-Weber syndrome. *J Child Neurol*. 2011;26(6):692–702.
78. Wang DD, Blümcke I, Coras R, et al. Sturge-Weber syndrome is associated with cortical dysplasia ILAE type IIIc and excessive hypertrophic pyramidal neurons in brain resections for intractable epilepsy. *Brain*. 2015;25(3):248–255.
79. Cohen JW, Walter AW. Hypothalamic Glioma in a patient with Sturge-Weber syndrome. *J Child Neurol*. 2016;38(1):e10–e12.
80. Wang S, Zhao M, Li T, et al. Stereotactic radiofrequency thermo-coagulation and resective surgery for patients with hypothalamic hamartoma. *J Child Neurol*. 2020;134:1019–1026.
81. Schropp C, Sörensen N, Krauss J. Early periinsular hemispherotomy in children with Sturge-Weber syndrome and intractable epilepsy—outcome in eight patients. *Epilepsia*. 2006;37(1):26–31.
82. Lettori D, Battaglia D, Sacco A, et al. Early hemispherectomy in catastrophic epilepsy: A neuro-cognitive and epileptic long-term follow-up. *Epilepsia*. 2008;17(1):49–63.
83. Wiebe S, Berg AT. Big epilepsy surgery for little people: What's the full story on hemispherectomy? *Epilepsia*. 2013;80(3):232–233.
84. Vadera S, Griffith SD, Rosenbaum BP, et al. National trends and in-hospital complication rates in more than 1600 hemispherectomies from 1988 to 2010: A nationwide inpatient sample study. *Epilepsia*. 2015;77(2):185–191; discussion 191.
85. Davidson AJ, Sun LS. Clinical evidence for any effect of anesthesia on the developing brain. *Anesth Analg*. 2018;128(4):840–853.
86. Raviraj D, Engelhardt T, Giedsing Hansen T. Safe anesthesia for neonates, infants and children. *Maturitas*. 2018;70(5):458–466.
87. Nelles M, Urbach H, Sassen R, et al. Functional hemispherectomy: Postoperative motor state and correlation to preoperative DTI. *Brain*. 2015;57(11):1093–1102.
88. Mori H, Aoki S, Abe O, et al. Diffusion property following functional hemispherectomy in hemimegalencephaly. *Acta Neurol Scand*. 2004;45(7):778–781.